

## MORPHOLOGICAL STUDY

# The topographical features and variations of nervus ischiadicus in human fetuses

Davut O<sup>1</sup>, Yakup G<sup>1</sup>, Sevgi B<sup>2</sup>, Senoglu M<sup>3</sup>, Kalender AM<sup>4</sup>, Calik M<sup>5</sup>

Department of Anatomy, Faculty of Medicine, Kahramanmaraş Sutcu Imam University, Kahramanmaraş, Turkey.  
davutozbag@hotmail.com

**Abstract:** *Background:* We aimed to investigate the topographical features and variations of ischiadic nerve during prenatal period in human.

*Methods:* Our study was conducted on lower extremities of 34 human fetal cadavers who were free of any anomalies and were obtained from the department of pathology of our faculty.

*Results:* When the development of topographical features of ischiadic nerve is considered according to the gestational weeks, it was shown that the distances increased in accordance with the age and there was a positive correlation between the two ( $p < 0.01$ ), however the width of the ischiadic nerve did not increase similarly and there was no significant correlation between its width and the age ( $p > 0.01$ ).

*Conclusions:* Understanding the structure and course of ischiadic nerve in both gluteal and femoral regions is important during all interventions to these regions due to the potential damage on the nerve itself. The knowledge of topographical features of ischiadic nerve in the prenatal period and its relations with reference points that are used especially in childhood and adults will help to follow up the variations during postnatal and grow up periods (Tab. 2, Fig. 4, Ref. 13). Full Text in free PDF [www.bmj.sk](http://www.bmj.sk).

Key words: topography, ischiadic nerve, fetus, human.

Nervus ischiadicus is composed of the anterior branches of spinal nerves L4, L5, S1, S2, S3 and forms at the apex of plexus sacralis. After traversing the pelvis it passes through the foramen infrapiriforme and reaches the gluteal region. Then it courses downward and laterally in front of the musculus gluteus maximus and reaches the posterior region of the thigh. Nervus ischiadicus continues its course posterior to the musculus adductor magnus until the distal 1/3 of this region and after then it splits into its terminal branches as nervus tibialis and nervus peroneus communis (1–6).

Intramuscular injection is a frequently and mainly employed procedure in medical practices. The two most frequent sites for injection are the upper lateral region of the buttock neighboring the ischiadic nerve and antero-lateral region of the thigh (1, 3, 6, 7).

Understanding the structure and course of ischiadic nerve in both gluteal and femoral regions is important during all inter-

ventions to these regions due to the potential damage on the nerve itself (2, 4, 5). Realizing the prenatal topographic features and variations of course of the ischiadic nerve thoroughly may lead to grasping of the variations of this region and the abnormal development of the nerve itself during the postnatal period. This information in turn enables us to avoid the injury to the nerve due to these variations.

Thus, we aimed to investigate the topographical features and variations of the ischiadic nerve during prenatal period in human.

## Materials and methods

Our study was performed on lower extremities of 34 human fetal cadavers (14–40 weeks) who were free of any anomalies and obtained from the department of pathology of our faculty. Local ethics committee approval was obtained prior to the study. The width of the ischiadic nerve (NIG) in the infrapiriform foramen, and the distances from the infrapiriform foramen to anterior superior iliac spine (SIAS), posterior superior iliac spine (SIPS), highest point of iliac crest (CI), ischiadic tubercle (TI), and trochanter major (TM) of femur by a millimetrically designed caliper were measured. The width of the ischiadic nerve (NIF) where it emerged to the gluteal region and where it passed from the gluteal region to the posterior femoral region at the level of the line connecting the ischiadic tubercle and trochanter major, and the distances from the ischiadic nerve to ischiadic tubercle and trochanter major of femur were also measured (Figs 1–4).

<sup>1</sup>Department of Anatomy, Faculty of Medicine, Kahramanmaraş Sutcu Imam University, Kahramanmaraş, Turkey, <sup>2</sup>Department of Pathology, Faculty of Medicine, Kahramanmaraş Sutcu Imam University, Kahramanmaraş, Turkey, <sup>3</sup>Department of Neurosurgery, Faculty of Medicine, Kahramanmaraş Sutcu Imam University, Kahramanmaraş, Turkey, <sup>4</sup>Department of Orthopaedics surgery, Faculty of Medicine, Kahramanmaraş Sutcu Imam University, Kahramanmaraş, Turkey, and <sup>5</sup>Department of Pediatrics, Faculty of Medicine, Zonguldak Karaelmas University, Zonguldak, Turkey

**Address for correspondence:** Davut O, MD, Dept of Anatomy, Faculty of Medicine, Kahramanmaraş Sutcu Imam University, 46050, Kahramanmaraş, Turkey.  
Fax: +0344 2212371

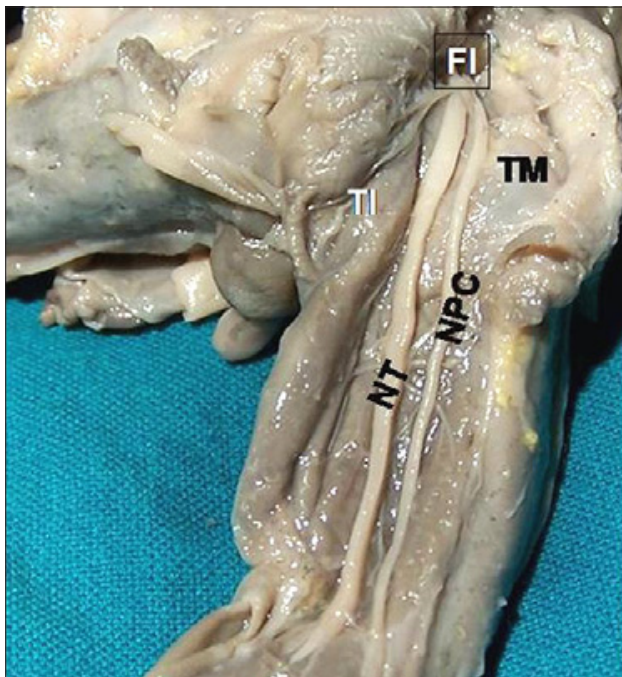


Fig. 1. Posterior view of the course of ischiadic nerve through buttocks and thigh in a fetus. FI – Foramen infrapiriforme, TI – Tuber ischiadicum, TM – Trochanter major, NT – Nervus tibialis, NPC – Nervus peroneus communis.

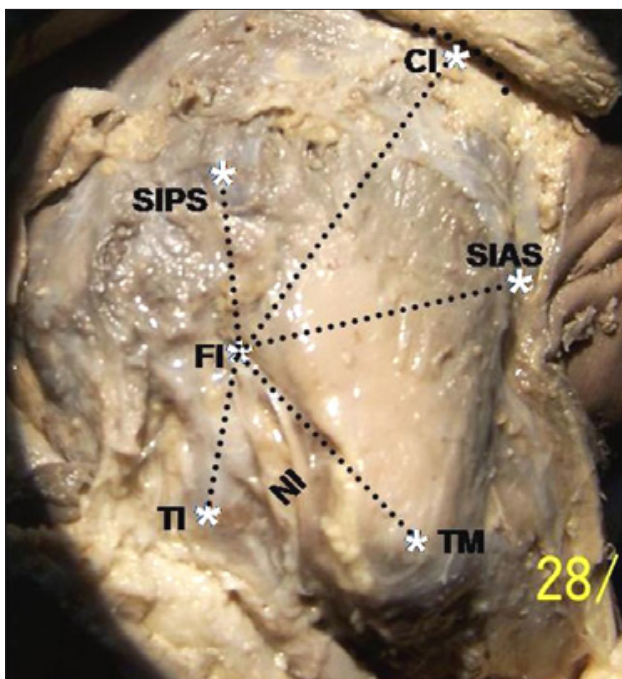


Fig. 2. The appearance of landmarks related to ischiadic nerve in gluteal region of right extremity. FI – Foramen infrapiriforme, SIAS – Spina iliaca anterior superior, CI – Crista iliaca, SIPS – Spina iliaca posterior superior, TI – Tuber ischiadicum, TM – Trochanter major, NI – Nervus ischiadicus.

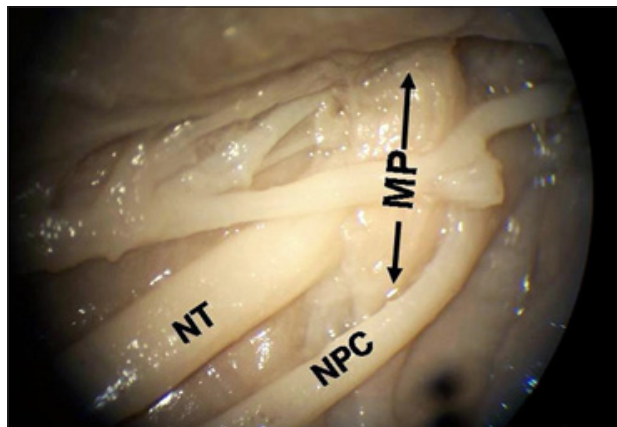


Fig. 3. A variation of ischiadic nerve. NT – Nervus Tibialis, NPC – Nervus Peroneus Communis, Musculus Piriformis (arrows).

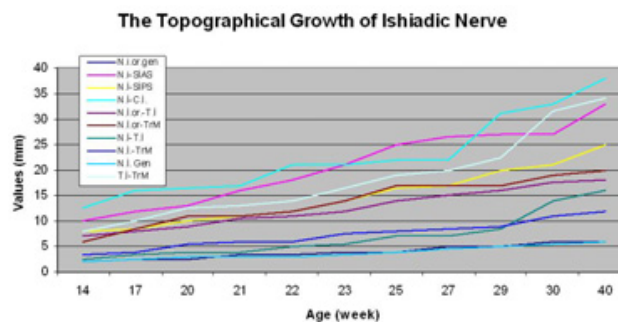


Fig. 4. The relationship between age and development of ischiadic nerve.

In addition, the variations of the ischiadic nerve in both gluteal and posterior femoral regions under the surgical microscope were investigated.

The statistical analyses were done with Spearman's rho correlation coefficient test (correlation was significant at 0.01 level).

### Results

The values measured were the width of NIG = 2–6 mm, NI-SIAS = 10–33 mm, NI-SIPS = 6–27 mm, NI-CI = 12–38 mm, NIG-TI = 7–18 mm, NIG-TM = 4–20 mm, NI-TI = 1.5–16 mm, NI-TM = 3–12 mm, width of NIF = 2–6 mm, TI-TM = 7–31.5 mm, and showed significant variations (Tabs 1, 2, Figs 1–4).

When the development of topographical features of the ischiadic nerve is considered according to the weeks, it was determined that the distances increased in accordance with the age and there was a positive correlation between the two ( $p < 0.01$ ), however the width of the ischiadic nerve did not increase similarly and there was no significant correlation between its width and the age ( $p > 0.01$ ) (Tabs 1, 2).

Besides, when the development of the rate of NI-TI / NI-TM with the age was evaluated, it was found that the change in this rate was not statistically significant ( $p > 0.01$ ). This finding sug-

**Tab. 1. The mean values (mm) of measurement in gluteal region in human fetuses.**

Week	NIG	NI-SIAS	NI-SIPS	NI-CI	NIG-TI	NIG-TM	NI-TI	NI-TM	NIF	TI-TM
14	2	10	8	12.5	7	6	2.5	3.5	2	8
17	2.5	12	8.5	16	8	8.5	3.5	4	2.5	10
20	2.5	13	10	16.5	9	11	4	5.5	3	12.5
21	3.5	16	11	17	10.5	11	4	6	3	13
22	3.5	18	12	21	11	12	5	6	3	14
23	4	21	14	21	12	14	5.5	7.5	3.5	16.5
25	4	25	16.5	22	14	17	7	8	4	19
27	5	26.5	17	22	15	17	7	8.5	4.5	20
29	5	27	20	31	16	17	8.5	9	5	22.5
30	6	27	21	33	17.5	19	14	11	5.5	31.5
40	6	33	25	38	18	20	16	12	6	34

**Tab. 2. The correlation of measurement values of the distances according to the weeks of development.**

Measurements	P
NI-SIAS (Nervus Ischiadicus–Spina Iliaca Anterior Superior)	<0.01
NI-SIPS (Nervus Ischiadicus–Spina Iliaca Posterior Superior)	<0.01
NI-CI (Nervus Ischiadicus–Crista Iliaca)	<0.01
NIG-TI (Nervus Ischiadicus (Gluteal)–Tuber Ischiadicum)	<0.01
NIG-TM (Nervus Ischiadicus (Gluteal)–Trochanter major)	<0.01
NIW (Nervus Ischiadicus Width)	<0.01
TI-TM (Tuber Ischiadicum–Trochanter major)	<0.01
NIGW (Nervus Ischiadicus Width)	>0.01
NI-TI/NI-TM (Nervus Ischiadicus–Tuber Ischiadicum/ /Nervus Ischiadicus–Trochanter Major)	>0.01

gests that the rate of NI-TI / NI-TM does not change markedly with age (Tabs 1, 2).

During the dissections, different variations were encountered in which nervus fibularis communis emerged from the foramen suprapiriforme and nervus tibialis emerged from the foramen infrapiriforme (1 on the left and 1 on the right out of 2 cases totally) or both nerves emerged from the foramen infrapiriforme (3 on the left and 1 on the right out of 4 cases totally) separately and coursed downwards to the region where it showed its classical distribution (Fig. 3).

**Discussion**

It is well known that injection injury is more likely to occur in individuals with a thin or poorly constructed buttock, such as those who are cachectic because of disease or old age. Injection-induced ischiadic nerve injury is a complication that results from inexperience and carelessness. Therefore, the buttocks should not be used as an intramuscular injection site in children, particularly those below the age of five years and in cachectic persons (1, 3, 6).

Sciatic injury rarely results from direct traumatic lesion of the nerve, but usually from the toxic effect of the injected drug. The likelihood of injury is increased if a long needle is used, if the hub of the needle depresses skin and subcutaneous tissues, or if the needle is angled toward the dipole or course of the nerve.

Incidence may also be increased if a patient receives an injection in the buttock while he or she is in a lateral and recumbent position or is standing and bent over (1, 8, 9).

The ischiadic nerve may be under pressure in many regions throughout its course, however the most frequent site of impingement is under the piriformis muscle. The cause of the impingement is mostly individual tendency and congenital anomalies (10). These essential variables has led us to conduct this study.

The knowledge of topographical features of ischiadic nerve in the prenatal period and its relations with reference points that are used especially in adults will enable us to follow up the variations during postnatal and grow up periods.

The neuropathy of the ischiadic nerve constitutes 96% of complications due to gluteal intramuscular injections. Since the intramuscular injection is frequently applied to the buttock, the course of the nerve is important in the gluteal region (8, 9, 11, 12, 13). However, to the best of our literature search, we could not come across any study performed on fetuses by the use of those reference structures or points. Therefore, we were not able to discuss our findings on the topography of the ischiadic nerve in the gluteal region with the results of others.

When the development of topographical features of the ischiadic nerve is considered according to the weeks, we determined that the distances increased parallel to the age and there was a positive correlation between the two (p<0.01), however the width of the ischiadic nerve did not increase similarly and there was no significant correlation between its width and the age (p>0.01). This fact can be explained with the more rapid development of the musculo-skeletal system than the nervous system elements (Tabs 1, 2).

When the function of the ischiadic nerve especially related to the motor and sensory activity of the lower extremity is considered, it is obvious that there will be a severe loss in the quality of life in patients who experience a possible nerve injury due to traumatic or toxic effects. Such injuries may be prevented or lessened to a minimum level through a detailed knowledge on the topographic features and variations of origin of the ischiadic nerve.

There were various reports in the literature especially on the variation of origin of the ischiadic nerve. We also came across

some case reports in which nervus fibularis communis emerged from the foramen suprapiriforme or through musculus piriformis and nervus tibialis emerged from the foramen infrapiriforme or both nerves emerged from the foramen infrapiriforme separately.

The most frequently observed variation of the ischiadic nerve in the gluteal region is the type in which nervus fibularis communis exits from between the fibers of musculus piriformis or foramen suprapiriforme and nervus tibialis exits from the foramen infrapiriforme (2, 3, 4, 5).

It was observed that nervus fibularis communis emerged from the foramen suprapiriforme and nervus tibialis emerged from the foramen infrapiriforme in 2 cases out of 34 (6 %), and both nerves emerged from the foramen infrapiriforme separately in 4 out of 34 cases (12 %).

The rate of nervus fibularis communis to exit from between the fibers of musculus piriformis or above it was reported as 7–33 % in the literature (Ozturk et al, 1998). Our findings in this study showed 6 % and it was close to the rate in the literature.

On the other hand, the rate of nervus fibularis communis and nervus tibialis to exit from the foramen infrapiriforme and course separately was reported as 7.5 % in the literature. This type of variation was encountered with a rate of 12 % in our study. The usual type of course of the ischiadic nerve as a common trunk of n.tibialis and n. fibularis communis exiting from the foramen infrapiriforme was reported to be 72.5 % in the literature and observed in 82 % in our study.

Such variations may bear clinical significance since m. piriformis may exert pressure on the ischiadic nerve and cause piriformis syndrome especially in cases with abnormal development types of the piriformis muscle (5).

The frequent existence of such variations increases the risk and incidence of injury to the ischiadic nerve (especially n. fibularis communis) during intramuscular injections to the inferomedial site of the superolateral quadrant of the gluteal region (1, 4, 7).

The importance of the developmental anomaly, variation and regional topographic features of the ischiadic nerve in the exposure of the nerve to toxic and traumatic effects in the gluteal region should never be neglected.

In conclusion, the topographic features of the ischiadic nerve in the gluteal region vary in accordance with the age. However the ratio between the distance from tuber ischiadicum to ischia-

dic nerve and the distance from trochanter major to ischiadic nerve at the level where the nerve passes from the gluteal to the posterior femoral region does not change with the age. We believe that those distances and variations of the nerve may give us valuable clues on the postnatal and other stages of development.

## References

1. **Kadioglu HH.** Injection-induced sciatic nerve injury: Is it a complication? *MJAU* 2004; 36: 65–70.
2. **Ozturk A, Bayraktar B, Arý Z, Sahinoglu K, Usta A, Arýsan E.** Common peroneal nerve emerging from piriformis muscle; an anatomical variational case. *J Istanbul Fac Med* 1998; 61: 1.
3. **Hoffmeister B.** Morphological changes of peripheral nerves following intraneural injection of local anesthetic. *Dtsch Zahnarztl Z* 1991; 46: 828–830.
4. **Ekinci N, Unur E, Yavasoglu OH, Ulger H.** Examination of ischiadic nerve and its clinical importance. *J Morphol* 1995; 3 (1): 21.
5. **Ozturk L, Bařaloglu H.** Research on the variations of ischiadic nerve. *Ege Univ J Fac Med* 1988; 27: 803.
6. **Masciocchi C, Innacoli M, Cisternino S, Barile A, Rossi F, Passariello R.** Myxoid intraneural cysts of external popliteal ischiadic nerve. Report of 2 cases studied with ultrasound, computed tomography and magnetic resonance imaging. *Eur J Radiol* 1992; 14: 52–55.
7. **Mayer M, Romain O.** Sciatic paralysis after a buttock intramuscular injection in children: an ongoing risk factor. *Arch Pediatr* 2001; 8: 321–323.
8. **Obach J, Aragonés JM, Ruano D.** The infrapiriformis foramen syndrome resulting from intragluteal injection. *J Neurol Sci* 1983; 58: 135–142.
9. **Kern H, Lachman E, Nagler W.** Sciatic nerve impingement from piriformis hematoma due to prolonged labor (letter). *Muscle-Nerve* 1995; 18: 789–790.
10. **Brodie DJ, Burnett JV, Walker JM.** Evaluation of low back pain by patients' questionnaires and therapist assessment. *JOSP* 1990; 11: 11.
11. **Aksoy C.** Frequent causes of low back pain other than disc herniation. In: Berker (Ed). *Current approaches in lumbar pain*. Istanbul: E. Tayf Ofset, 1994.
12. **Cox JM.** *Low Back Pain*. 5th Ed. Baltimore: Williams and Wilkins, 1991.
13. **Vos LD, Bom EP, Vroegindewij D.** Congenital pelvic arteriovenous malformation: a rare cause of sciatica. *Clin Neurol Neurosurg* 1995; 97: 229–232.

Received May 5, 2009.

Accepted April 4, 2011.