

TOPICAL REVIEW

The use of platelet rich plasma with guided tissue regeneration in defects caused by periodontal diseases

Holly D, Mracna J

Department of Dentistry and Maxillofacial Surgery, Comenius University, St. Elisabeth's Hospital, Bratislava, Slovakia. dholly@chello.sk

Abstract: The goal of periodontal treatment is not only the stabilization of disease but also the regeneration of the destructed tissue. In the past few years various procedures have been created to achieve this. The guided tissue regeneration is a surgical procedure developed on the basis of experimental studies. It enables the creation of periodontal tissues affected by periodontitis, the so called reattachment. It stands for formation of new attachment – meaning the regeneration of cementum, alveolar bone and periodontal ligament. This surgical procedure of the treatment of periodontitis is based on the principle of exclusion of the epithelium and also the gingival connective tissue from the root surface so the precursor cells (desmodontal cells) can occupy the defect and pursue their differentiation. Periodontal ligament containing cells with regenerative potential are the exclusive ones to have the ability to regenerate structures affected by periodontitis. The use of growth factors offer new aspects to the therapy (Fig. 7, Ref. 11). Full Text (Free, PDF) www.bmj.sk.
Key words: guided tissue regeneration, platelet rich plasma, periodontal defects.

Guided tissue regeneration is a clinical method enabling regeneration of periodontal tissue of teeth damaged by periodontitis, by allowing the cells of periodontal tissue – desmodonts – to cover the surface of the tooth root. This can be achieved by placing an occlusive membrane, which forms the space between the membrane and the surface of the root, in which tissues of periodontal apparatus may grow. Membrane also prevents proliferation of gingival epithelium and connective tissue to the root surface during healing (4).

An important requirement for controlled tissue regeneration is the ability to maintain a membrane-protected space of the defects and its resistance to collapse due to pressure of mucoperiosteal flaps. This refers mainly to resorbable membranes, which lose their mechanical resistance during the degradation process. In this case it is necessary to use additional supporting techniques. Membranes have a two-layer structure. One layer is porous and attached to the bone, which allows it to grow into the defect. The mucoperiosteal flap is attached to the second, compact layer. This will prevent the growth of the soft tissue in the treatment wounds. The structure of the membrane is maintained even in wet environments and should be used in combination with supporting material to fill the defect (5).

Methods

One of the most important goals of the therapy is to eliminate deep periodontal pockets, because they serve as reservoirs

of a constantly increasing number of pathogenic anaerobic microorganisms. Reduction (or elimination) of the pocket's depth can be achieved by resective or regenerative surgical methods or a combination of both. Regenerative process in periodontology represents the use of guided tissue regeneration – GTR.

Indications in periodontology (1, 2, 3, 8, 10)

- Furcations II. grade in the mandible and in maxilla buccally.
- III. grade in the mandible, if the vertical diameter is ≤ 3 mm (Type A 1–3 mm) (Tarnow and Fletcher, 1984)
- Bone defects 1, 2, 3 – wall (by a 1-wall defect a bone graft is needed)

Contraindications

- Local factors – inadequate plaque control
- teeth with insufficient endodontic therapy
- moving teeth without stabilization
- Systemic factors – smoking
- decompensated diabetes mellitus
- other systemic diseases, which can affect the treatment options

Clinical use

There are different materials in clinical use. In our cases we used hydroxiapatite (HA, an alloplastic synthetic graft) and a collagen membrane. For a complete regeneration of periodontal structures, including cementum, ligaments, bone and gum an interplay between multiple pluripotent cells is necessary – extracellular matrix and matrix proteins, systemic hormones as well

Department of Dentistry and Maxillofacial Surgery, Comenius University, St. Elisabeth's Hospital, Bratislava, Slovakia

Address for correspondence: D. Holly, MD, Dept of Dentistry and Maxillofacial Surgery, Comenius University, St. Elisabeth's Hospital, Heydukova 10, SK-812 50 Bratislava, Slovakia.

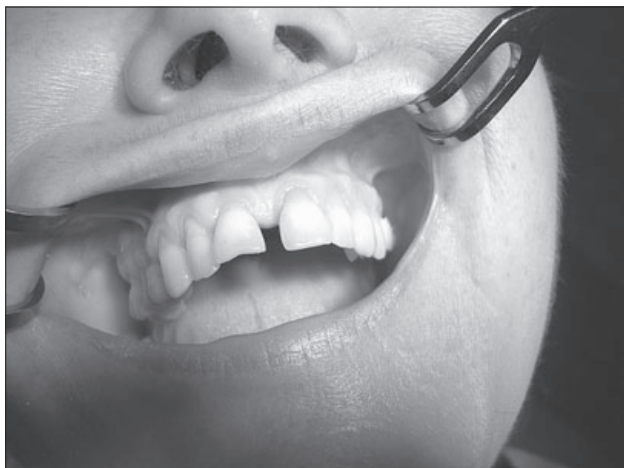

Fig. 1. Inflammation free status of the patient before surgery.

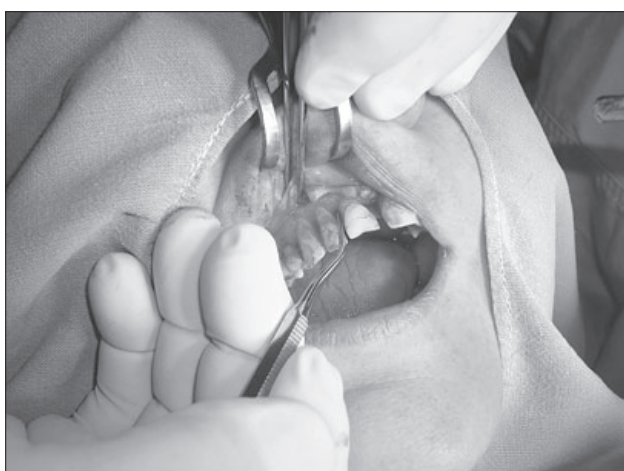

Fig. 2. Reflection of mucoperiosteal flaps and the revision of the pockets.

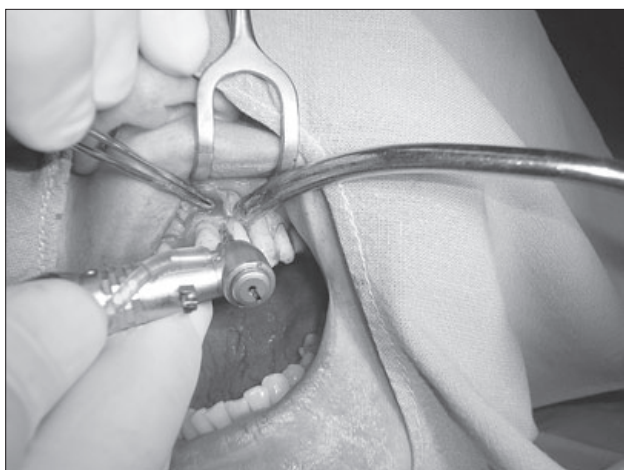


Fig. 3. Osteoplasty of the alveolar bone.

as growth and differentiation factors. Of these the most important factors include:

- PDGF – platelet-derived growth factor
- IGF – insuline-like growth factor

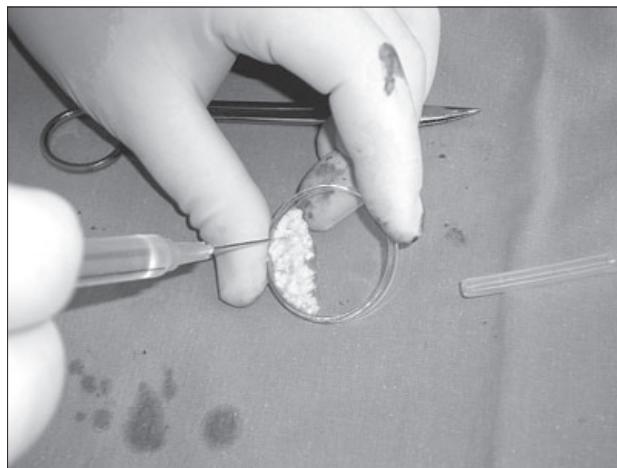


Fig. 4. Preparation of the synthetic graft with PRP.

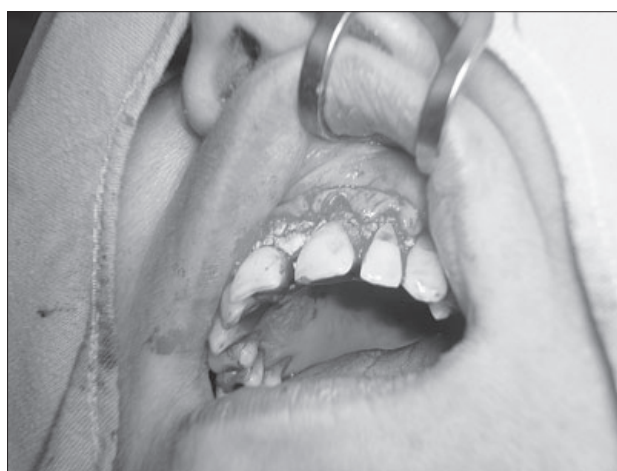

Fig. 5. Application of the graft material in to the wound.

- TGF- β – transforming factor beta
- BMP – bone morphogenetic proteins -2, -4, -7
- FGF – fibroblast growth factor (1, 2, 3, 9, 11):

These factors are increasingly being used for enhancement and improvement of the healing of periodontal tissue. Increasing the level of growth factors leads to improvement of bone regeneration. At the same time the growth factors accelerate the healing of soft tissue around the bone. To achieve this in clinical conditions platelet rich plasma (plasma rich in platelets, PRP) is used. It is prepared from patient's venous blood before surgery and separated in a blood bank. Its benefits are as follows:

- accelerates endothelial, epithelial and epidermal regeneration
- stimulates angiogenesis
- supports collagen synthesis and increases the strength of re-generated tissue,
- is hemostatic,
- organizes blood, which reduces postoperative hematoma and edema,
- reduces the pain and thereby reduces consumption of analgesics in post-operative period,

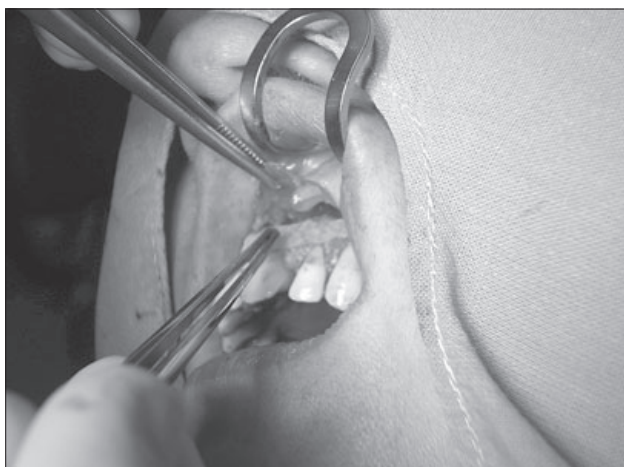

Fig. 6. Application of the collagenous membrane.

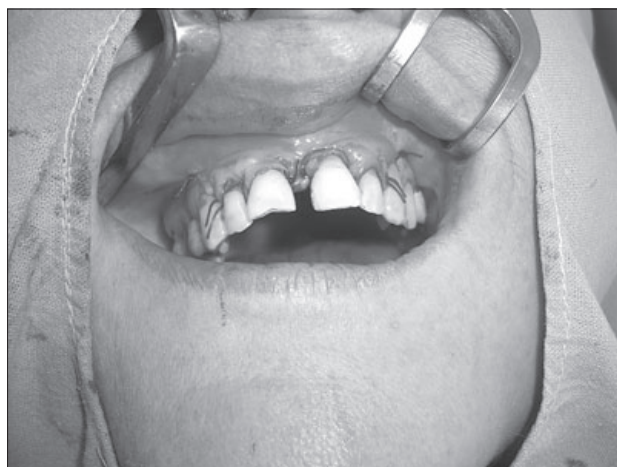

Fig. 7. Wound closure.

- accelerates the deposition of extracellular matrix and thereby seals the wound,
- excludes the possibility of transmission of infection and immune response (autologous material) (6).

Results and discussion

Prior to patient's surgery a good oral hygiene has to be secured, a prepared, inflammation free status of the periodontal tissue is necessary (Fig. 1). The actual surgery is based on the reflection of mucoperiosteal flaps (buccal, vestibular and palatal, lingual side), curettage of deep pockets, removal of granulomatous tissue from the the pockets and from surrounding soft tissue (Fig. 2), removal of residuous subgingival dental stone and the necrotic parts of the root cementum. After osteoplasty of the sharp edges of the alveolar bone (Fig. 3) the material for filling of the defect is prepared. In a sterile dish a graft (hydroxyapatite in this case), and PRP are mixed and calcium is added, which starts the process of precipitation, leading to the creation of "trombocytal gelee" (Fig. 4). The gelous form has ideal prerequisites to fill in the bone defect. Before its application to the defect, the loading of auxiliary stitches is recommended. Their suture follows after application of the gelee, and the overlap with a collagenous membrane (Figs 5, 6). Then we adapt the mucoperiosteal flaps and finish with a definitive suture (Fig. 7). Antibiotics and disinfecting solutions containing chlorhexidine are prescribed to the patient postoperatively. We monitor the process of osteogenesis and regeneration. After nine months we evaluate the success of the operation – new periodontal rebuilt structures and the X-ray is made to evaluate the bone tissue.

Conclusion

The management of tissue and bone regeneration in surgical techniques are widely used for regeneration of damaged oral structures. The growth factors by the use of platelet rich plasma bring new aspects for therapy of periodontal diseases. Our cur-

rent focus points at the improvement of these interventions using regenerative factors, which are gradually becoming part of standard clinical practice.

References

1. Becker W, Becker BE, Mellonig J et al. A prospective multi-centered study evaluating periodontal regeneration for class II furcation invasions and intrabony defects after treatment with a bioresorbable barrier membrane: 1 year results. *J Periodontol* 1996; 67: 641–649.
2. Cortellini P, Pini Prato G, Tonetti MS. Periodontal regeneration of human infrabony defects with titanium reinforced membranes. A controlled clinical trial. *J Periodontol* 1995; 66: 797–803.
3. Cortellini P, Pini Prato G, Tonetti MS. Periodontal regeneration of human intrabony defects with bioresorbable membranes. A controlled clinical trial. *J Clin Periodontol* 1996 67: 217–223.
4. Fassmann A, Vaněk J, Dvořáková N, et al. Řízená tkáňová a kostní regenerace ve stomatologii. Praha: GRADA, 2002, 200 p. 5. Jurkovič R. Augmentačné materiály používané v zubnom lekárstve — súčasťný stav. *Čes Stomatol* 2005; 105 (5): 135–138.)
6. Marx RE, Carlson ER, Eichstaedt RM, Schimmele SR, Strauss JE, Georgeff KR. Platelet rich plasma: Growth factor enhancement for bone grafts. *Oral Surg Oral Med Oral Pathol* 1998; 85: 638–646.
7. Newman MG, Takei HH, Klokkevold PR, Carranza FA et al. Carranza's Clinical Periodontology, St. Louis: Saunders Elsevier, 2006, 1328 p.
8. Stellungnahme der Deutschen Gesellschaft für Zahn-, Mund- und Kieferheilkunde, Liesegangstr. 17 a - 40211 Düsseldorf, Stand 06/1999.
9. Tonetti MS, Pini Prato G, Cortellini P. Periodontal regeneration of human infrabony defects. IV. Determinants of healing response. *J Periodontol* 1993; 64 (10): 934–940.
10. Vojtassak J, Bakos D, Danihel L, Kristin J, Böhmer D, Danisovic L, Blasko M. In vitro cytotoxicity testing of coladerm membrane. *Cell Tissue Bank* 2001; 2 (4): 225–233.
11. Wolf HF, Rateitschak EM, Rateitschak KH, Hassel TM, et al. Periodontology — Color Atlas of Dental Medicine. Stuttgart: Georg Thieme Verlag, 2005, 534 p.

Received March 23, 2009.

Accepted June 26, 2009.