

## CASE REPORT

## A variant of Buhler's arc formed by the unusually long dorsal pancreatic artery

Jiji PJ, Soubhagya R Nayak, Sujatha D'Costa, Latha V Prabhu, Mangala M Pai, Merin T

Department of Anatomy, Centre for Basic Sciences, Bejai, Kasturba Medical College, Mangalore, Karnataka, India. [pj.jiji@gmail.com](mailto:pj.jiji@gmail.com)

**Abstract:** The knowledge of anatomical variations of the vascular junction between the celiac trunk and superior mesenteric artery is surgically significant. A case of unusually long dorsal pancreatic artery that originated from the common hepatic artery and directly anastomosed with the middle colic artery thus forming a rarely reported variant of Böhler's arcade is presented (Fig. 1, Ref. 14). Full Text (Free, PDF) [www.bmj.sk](http://www.bmj.sk). Key words: Böhler's arcade, dorsal pancreatic artery, common hepatic artery.

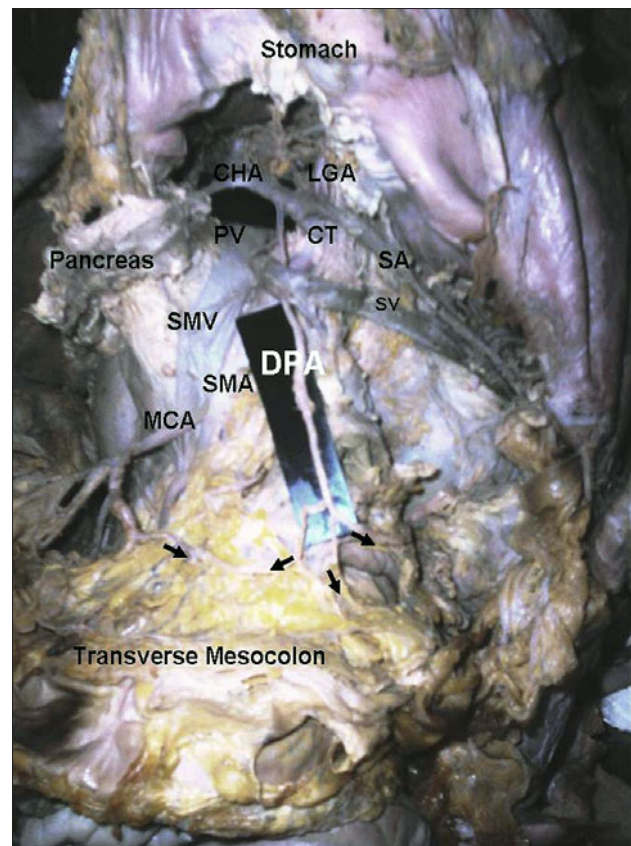
The dorsal pancreatic artery (DPA) is commonly a branch of proximal part of the splenic artery; lying posterior to both the neck of pancreas and splenic vein, and after giving few pancreatic branches, usually terminates into a left branch, the transverse pancreatic, and a right branch, which unites with the superior pancreaticoduodenal or the gastroduodenal artery (1).

The DPA was regarded by Pierson as subject to considerable variation in regard to origin, presence, and size (2). However, discordant opinions exist on its various origins, not in its incidence. As per the reports of Bergman et al, the dorsal pancreatic artery arose from the splenic in 37 % of cases, the celiac in 33 %, the superior mesenteric in 21 %, and the common hepatic artery in 8 % of cases (3). But according to Matsumura, the parent artery of the DPA was the superior mesenteric artery (55.0 %), accounting for 45.0 % of the entire celiac trunk (4). Thus the dorsal pancreatic artery may originate from the celiac trunk or from the superior mesenteric artery. When these two connections remain present, which is rather rare (1–2 %), it forms a small vertical arch called the arc of Böhler (5).

We present a case of dorsal pancreatic artery that originated from the common hepatic artery, and communicated with the middle colic artery thus forming a rarely described variant of Böhler's arcade. A somewhat similar case was reported in 1989 by Makomaska-Szaroszyk (6).

### Case report

During dissection of the abdomen of an approximately 55 year old male cadaver, we observed a long dorsal pancreatic



**Fig. 1.** Dorsal pancreatic artery anastomosing with middle colic artery: In the photograph, the pancreas is reflected to the right and the stomach is reflected upwards to show the the origin of the dorsal pancreatic artery (DPA) and the anastomosis of its right terminal branch with the middle colic artery (MCA) forming Böhler's arc. CHA – common hepatic artery, SV – splenic vein, MCA – middle colic artery, PV – portal vein, SMV – superior mesenteric vein, SMA – superior mesenteric artery, CT – coeliac trunk, SA – splenic artery, and LGA –left gastric artery, arrows represent the diverging branches of DPA.

Department of Anatomy, Centre for Basic Sciences, Bejai, Kasturba Medical College, Mangalore, Karnataka, India.

**Address for correspondence:** Jiji, PJ, MSc, Dept of Anatomy, Centre for Basic Sciences, Bejai, Kasturba Medical College, Mangalore, Karnataka, India, PIN-575004.

Phone: +91.824.2211746, Fax: +91.824.2428183

artery arising from the common hepatic artery, close to the coeliac trunk. It coursed down behind the body of the pancreas and splenic vein. It supplied two branches to the posterior surface of the pancreas and descended just medial to the duodeno-jejunal flexure after giving the transverse pancreatic branch that coursed along the inferior border of pancreas. Almost 11.5 cm distal to its origin, within the transverse mesocolon, the artery bifurcated; the left branch, after giving a straight branch to the transverse colon, continued further to anastomose with the left colic artery whereas the right branch anastomosed with the left branch of the middle colic artery (Fig. 1).

## Discussion

The extensive arterial network of the pancreas is an important source of collateral blood supply in cases of occlusion of coeliac axis, superior mesenteric or splenic arteries (7). Other than the gastroduodenal artery and the pancreaticoduodenal arcade, the dorsal pancreatic artery also provides efficient collateral blood flow in coeliac axis stenosis, depending on its origin and extent, as it lies at the vascular junction between the coeliac trunk and superior mesenteric artery. The transverse pancreatic branch of DPA could be surgically significant as it may often be large enough to furnish a second major vessel to the spleen (8). The DPA is often found giving origin to an artery to the transverse mesocolon either directly as an accessory middle colic or accessory lateral colic artery, or through its transverse pancreatic branch as posterior epiploics (1, 8, 9, 10). If so, during surgical intervention of the pancreas or the supposedly avascular area of transverse mesocolon, there is a risk of injuring the middle colic artery or rather, the variants of Bühler's arc (6, 11, 12). The arc of Bühler is an embryological persistence of the portion of the ventral longitudinal anastomosis (13). Reproducing three cases of an anastomotic arterial trunk between the coeliac artery and the superior mesenteric artery, Bertelli et al stressed upon the importance of this anastomosis in pancreatic surgeries although its incidence is rather rare i.e., 0.4 % in vivo (11). As per Bühler, the incidence is 1–2 % (5). However, the incidence of the arc of Bühler is believed to be  $\leq 4$  %. Aneurysms of this rare variation are even more uncommon but have been reported in association with stenoses or occlusions of coeliac origin (14).

The knowledge of anatomical variations of the vascular junction between the coeliac trunk and superior mesenteric artery

can aid a surgeon in vital decision-making about the surgical procedure to be adopted while performing pancreatectomies, splenectomies and resections.

## References

1. **Michels NA.** The hepatic, cystic and retroduodenal arteries and their relations to the biliary ducts, with samples of the entire coeliac blood supply. *Ann Surg* 1951; 133 (4): 503–524.
2. **Pierson, JM.** The arterial blood supply of the pancreas. *Surg Gynecol Obstet* 1943; 77: 426–432.
3. **Bergman RA, Thompson SA, Afifi AK, Saadeh FA.** Compendium of human anatomic variations. Baltimore-Munich; Urban & Schwarzenberg, 1988: 79.
4. **Matsumura.** The significance of the morphology of the dorsal pancreatic artery in determining the presence of the accessory right hepatic artery passing behind the portal vein. *Kaibagoku Zasshi* 1998; 73 (5): 517–527.
5. **Bühler A.** Über eine Anastomose zwischen den Stämmen der A. Coeliaca und der A. Mesenterica Superior. *Morpholog Jahrb* 1904; 32: 185–187.
6. **Makomaska-Szaroszyk E, Fiedor P.** A rare case of anastomosis between the dorsal pancreatic artery and the middle colic artery. *Folia Morphol (Warsz)* 1989; 48 (1–4): 147–149.
7. **Kadir S.** Atlas of normal and variant angiographic anatomy. Philadelphia; Saunders, 1991: 297–309.
8. **Michels NA.** The variational anatomy of the spleen and splenic artery. *Amer J Anat* 1942; 70: 21.
9. **Woodburne RT, Oslen LL.** The arteries of the pancreas. *Anat Rec* 1951; 111 (2): 255–270.
10. **Michels NA.** Blood supply and anatomy of the upper abdominal organs with a descriptive atlas. Philadelphia; Lippincott, 1955: 139–165.
11. **Bertelli E, Gregorio F, Civeli L.** Various cases of direct connection between the coeliac artery and the superior mesenteric. *Arch Ital Anat Embriol* 1991; 96 (4): 281–289.
12. **McNulty JG, Hickey N, Khosa F, O'Brien P, O'Callaghan JP.** Surgical and radiological significance of variants of Bühler's anastomotic artery: a report of three cases. *Surg Radiol Anat.* 2001; 23 (4): 277–280.
13. **Tandler J.** Über die Varietäten der Arteria Coeliaca und deren Entwicklung. *Anat Hefte* 1904; 25: 473–500.
14. **Dubel GJ, Ahn SH, Saeed MA.** Interventional Management of Arc of Bühler Aneurysm. *Semin Intervent Radiol* 2007; 24: 76–81.

Received February 8, 2008.

Accepted April 18, 2008.